

p53 mutation and protein alteration in 50 gliomas. Retrospective study by DNA-sequencing techniques and immunohistochemistry

K. von Eckardstein¹, H. Gries¹, E. Bolik¹, J. Cervós-Navarro¹, I.N. Tschairkin¹ and S. Patt^{1,2}

¹Institute of Neuropathology, Free University of Berlin, Berlin, Germany and

²Institute of Pathology, Friedrich-Schiller-University Jena, Jena, Germany

Summary. Alterations of the p53 protein, which is a 53 kD phosphoprotein and gene product of the p53 gene, has been found to play a major role in the genesis of a variety of human malignancies including tumors of the central nervous system.

We investigated 50 tumor specimens from primary central nervous system neoplasms. Tissue samples were screened for mutations by the single-strand conformation polymorphism method and detected mutations were sequenced. All tissue specimens were stained immunohistochemically for p53 protein, which when altered accumulates in the nucleus due to prolonged half-life.

Mutations were found in six cases, including one pilocytic astrocytoma World Health Organisation (WHO) grade I, two astrocytomas WHO grade II, two anaplastic astrocytomas WHO grade III, and one primitive neuroectodermal tumor (PNET). In terms of relative frequency mutations were found mostly in the group of anaplastic astrocytomas WHO grade III. Interestingly, no mutations were found in the group of investigated glioblastomas. P53 immunopositivity did not correlate with the mutations found, whereas the staining index was significantly higher in the cases with detected mutations than in those without.

When p53 alteration is seen as an indicator for different pathogenic pathways in glioma formation, this study gives evidence for a difference between anaplastic astrocytoma and glioblastoma. However, since there was a great overlap in p53 immunopositivity and p53 mutation in tumors of different WHO grades and entities, it seems that p53 will not act as a marker molecule neither for tumor entities nor for tumor malignancy.

Key words: Glioma, p53, DNA sequencing, Immunohistochemistry, Diagnosis

Introduction

The p53 protein was identified as an intranuclear phosphoprotein with a molecular weight of 53 kD. Mutations in the p53 gene have been found to be the most frequent genetic alteration in human malignancies, such as tumors of the colon, breast, lung, liver, and the brain (Nigro et al., 1989; Lazaris et al., 1995; Sirvent et al., 1995).

The wildtype p53 protein shows DNA binding abilities, which reflect its role as a tumor suppressor. Louis (1994) summarized its function as a guardian of the genome in four cellular pathways, which lead to arrest of the cell in G₁-phase of the cell cycle, to initiation of DNA repair, to induction of apoptosis, and to promotion of cell differentiation. These cellular pathways lead to efficient repair or at least elimination of damaged DNA. After irradiation for instance, a higher level of p53 protein is detectable in the nucleus, whereas in normal tissues only very small amounts of the protein are measurable.

In comparison to the half-life of 20 to 30 min of the wildtype p53 protein, the mutant gene encodes for a pathological protein with a half-life of 24 hours. Therefore, mutant p53 protein can accumulate in cells, although it cannot function properly due to inactivation. Viral proteins, for instance, such as SV40 large-T-protein or adenovirus E1b-protein, can bind to p53 protein and lead to inactivation. Lack of functioning of p53 protein, either by genetic mutation or by inactivation, can initiate a selection of malignant cell clones and may therefore contribute to tumor progression (Louis, 1994). Other investigators have demonstrated p53 gene alteration to be an early step in tumor formation that may contribute to tumorigenesis as well (von Deimling et al., 1992; Kleihues et al., 1994; Koga et al., 1994).

Different studies have been conducted to evaluate the role of p53 gene mutation in tumors of the central nervous system (CNS). p53 mutations in astrocytomas were first described in 1989, in other CNS tumors p53 mutation has also been found (Nigro et al., 1989).

Alteration of p53 gene and protein in gliomas

Nevertheless, they are rare in oligodendrogliomas and medulloblastomas (Ohgaki et al., 1993).

This study presents a set of 50 primary brain tumors, examined for mutations of p53 gene by means of single-strand conformation polymorphism (SSCP) and sequencing methods and for alteration in the p53 protein by means of immunohistochemistry. We examined the use of routine paraffin-embedded material for SSCP technique in a modified silver staining technique, which has not been in the scope of earlier studies on CNS tumors. We demonstrate the correlation between genetic analysis and immunohistochemistry, and genetic analysis and grade of malignancy. We focus mainly on the issue of p53 alterations and their diagnostic relevance.

Materials and methods

Paraffin-embedded material of 84 primary CNS tumors from 83 patients was analysed in this study. In one case material from both the first operation and recurrence was investigated. The patients underwent tumor resection between 1987 and 1991 at the Humboldt University, Charité, Berlin.

Hematoxylin and Eosin (HE)-stained sections were classified according to the World Health Organization (WHO) classification (Kleihues et al., 1993) by a neuropathologist (SP).

DNA was extracted from paraffin-embedded sections by standard procedures. Exons 5 to 9 of the p53 gene were amplified by polymerase chain reaction (PCR) according to the protocol by McPherson et al. (1991). Amplification products were denatured (95 °C for 5 min) and separated on 8% bisacrylamide gel for 26 hours at 20 mA and 200 V. Separated DNA was stained by silver staining technique according to Wray et al. (1981) and the result was documented by photographic means.

Those exons that showed an atypical migration pattern on SSCP were sequenced according to Sanger et al. (1977). The results were documented autoradiographically. Negative controls were included in PCR and SSCP techniques.

Alkaline phosphatase-anti alkaline phosphatase (APAAP) was the technique used in immunohistochemical evaluation of p53 antigen. The primary antibody PAb1801, obtained from Dainova, Germany, was diluted 1:1000. The sections were counterstained with haemalaun. As negative control sections of normal brain tissue were used, positive controls were performed by a section of a highly immunopositive glioblastoma multiforme. The staining index (SI), i.e. number of immunopositive cells to the total number of cells in five high power fields (x40 objective), was obtained as result of p53 immunohistochemistry. Only those cells with definite staining of the nucleus were considered positively stained.

«SPSS for windows» was used for statistics. The correlation coefficients were calculated for the dependencies of two constant variables, whereby the

significance level $p=0.005$ was maintained. The rank sum test for two independent groups was performed by the Mann-Whitney U-test.

Results

Amplification and sequencing evaluation

Of the 84 specimens, we were able to amplify the DNA of 50 tumor cases (62.5%). Therefore, molecular studies could only be performed on this limited number of cases, including seven pilocytic astrocytomas (WHO grade I), two oligodendrogliomas (WHO grade II), one oligoastrocytoma (WHO grade II), 19 low grade astrocytomas (5 WHO grade I, 14 WHO grade II), six anaplastic astrocytomas (WHO grade III), 14 glioblastomas, and one primitive neuroectodermal tumor (PNET).

All 50 cases were screened by SSCP analysis, six tumors showing a distinctly different migration pattern of PCR products. Sequencing was successful in five of these six cases.

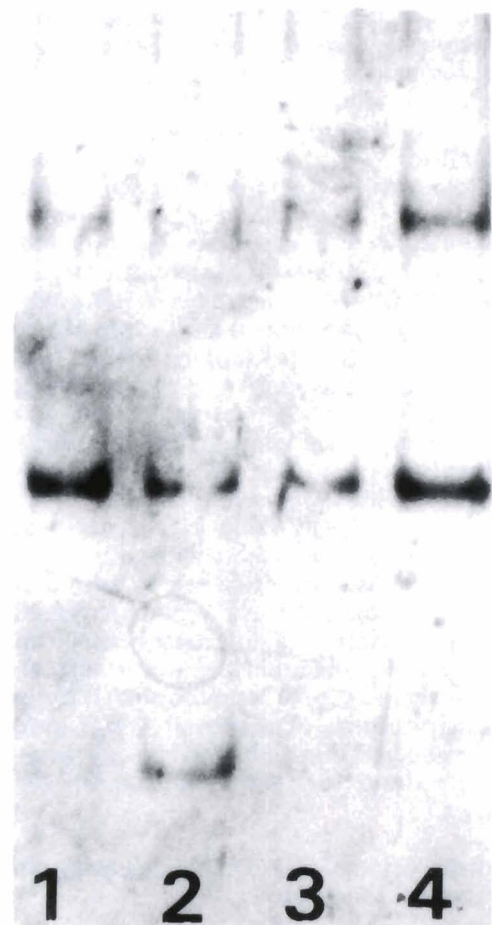


Fig. 1. SSCP evaluation of exon 7. Lanes 1, 3, and 4. Tumor samples without detectable mutation. Lane 2. Tumor sample of anaplastic astrocytoma #1 (see Table 1) with atypical migration pattern.

Alteration of p53 gene and protein in gliomas

In one of seven pilocytic astrocytomas SSCP and sequencing revealed a silent mutation in exon 9, codon 324 (GAT→GAC, Asp→Asp). In 19 astrocytomas of low malignancy (WHO grade I and II) two cases showed a different migration pattern in SSCP concerning exons 5 and 7, respectively. Further sequencing was not possible in one case due to the small amount of extracted DNA, insufficient for further processing. The other case demonstrating an atypical migration pattern concerning exon 5 in SSCP revealed a point mutation in codon 151 (CCC→CTC, Pro→Leu).

In two of six anaplastic astrocytomas SSCP showed a remarkable pattern concerning exons 7 and 8. The sequencing of the first anaplastic astrocytoma revealed two mutations in exon 8, of which one was a point mutation in codon 281 (GAC→GAG, Asp→Glu) and the other a point mutation in codon 282 (CGG→TGG, Arg→Trp). The second anaplastic astrocytoma exhibited a point mutation in exon 7, codon 245 (GGC→AGC, Gly→Ser) (Figs. 1, 2).

The only PNET involved in this study also showed a point mutation in exon 7, codon 245 (GGC→AGC, Gly→Ser). The other samples were not sequenced because of negative SSCP results. The low grade oligodendrogliomas (WHO grade II) and the low grade oligoastrocytoma (WHO grade II) studied did not show any mutations in SSCP screening.

In summary, one of seven pilocytic astrocytomas WHO grade I (14.3%), two of 19 low grade astrocytomas WHO grade I and II (10.5%), two of six anaplastic astrocytomas WHO grade III (33.3%), and one of one PNET WHO grade IV (100%) showed mutations. None of fourteen glioblastoma WHO grade IV (0.0%) showed mutations. There is hence no correlation between p53 gene mutation and tumor malignancy in our series.

Immunohistochemistry and staining index evaluation

The immunohistochemical p53 protein staining showed immunopositivity in 36 of the 50 cases, in which PCR was successful. Because of unsuccessful DNA

amplification in the remaining 34 of the total 84 cases, these cases were excluded from immunohistochemical analysis.

One of two oligodendrogliomas (50%) one of one oligoastrocytoma (100%), one of five astrocytomas WHO grade I (20%), and eleven of 14 astrocytomas WHO grade II (78.6%) showed immunopositivity with the antibody against p53 protein. Six of six studied anaplastic astrocytomas (100%), four of seven pilocytic astrocytomas (57.1%), eleven of 14 glioblastomas (78.6%), and the only PNET (100%) showed positive nuclei as well.

With regard to the SI a slightly different pattern could be evaluated. Of 46 tumors with astrocytic origin 33 specimens (71.1%) showed immunopositivity, of which 20 neoplasms had a low SI of less than 1%. Allocating the average SI within the astrocytic groups of positive staining to the tumor entities we received the following results. The astrocytomas WHO grade I had an average SI of 0.1%, the pilocytic astrocytomas WHO grade I of 0.3%, the astrocytomas WHO grade II of 3.3%, the anaplastic astrocytomas of 20.8%, and the glioblastomas of 5.0%. The correlation of average SI to malignancy of the astrocytic tumors (WHO grade I and II versus WHO grade III and IV) was significant ($r=0.34$, $p\leq 0.05$). However, a great overlap was found within the WHO grades. The immunopositive oligo-dendrogloma had a SI of 8.7%, whereas the oligoastrocytoma showed 0.1% positive nuclei. The only studied PNET had an SI of 31.1%.

In summary, the correlation of SI to the presence of p53 mutation was significant. The average SI of specimens without mutation was significantly lower than the SI in cases with mutation ($r=0.30$, $p\leq 0.05$). All data presented above are included in the table (Table 1), grouped according to diagnosis.

Discussion

The mutations described in previous studies were point mutations which were missense mutations in most cases. According to Louis (1994) and Böglér et al.

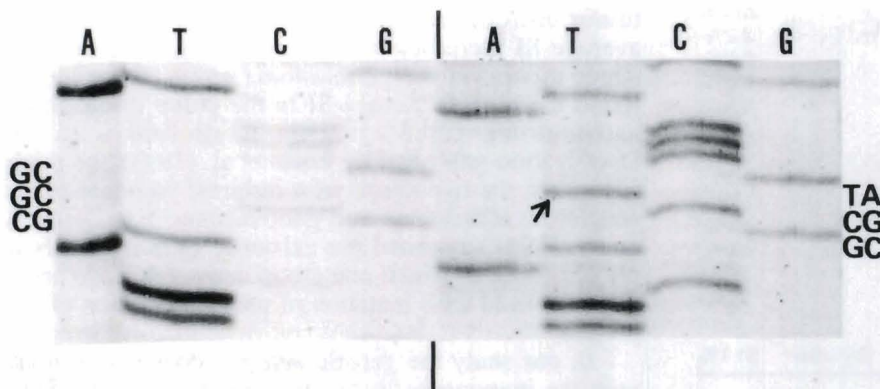


Fig. 2. Sequencing of exon 7. **Left lane.** Tumor sample with wildtype sequence. **Right lane.** Tumor sample of anaplastic astrocytoma #1 (see

Alteration of p53 gene and protein in gliomas

Table 1. p53 mutation and immunohistochemistry

SPECIMEN#	SSCP	CODON#	BS	AAS	SI
<i>Pilocytic astrocytoma, grade I</i>					
1	negative				0.7%
2	negative				0.3%
3	negative				0.2%
4	negative				0.1%
5	exon 9		GAT→GAC	Asp→Asp	0.0%
6	negative				0.0%
7	negative				0.0%
<i>Astrocytoma, grade I</i>					
1	negative				0.1%
2	negative				0.0%
3	negative				0.0%
4	negative				0.0%
5	negative				0.0%
<i>Astrocytoma, grade II</i>					
1	negative				19.2%
2	exon 7	no result	no result	no result	5.5%
3	negative				5.0%
4	negative				2.4%
5	negative				2.4%
6	exon 5	151	CCC→CTC	Pro→Leu	0.5%
7	negative				0.7%
8	negative				0.2%
9	negative				0.1%
10	negative				0.1%
11	negative				0.1%
12	negative				0.0%
13	negative				0.0%
14	negative				0.0%
<i>Oligoastrocytoma, grade II</i>					
1	negative				0.1%
<i>Oligodendroglioma, grade II</i>					
1	negative				8.7%
2	negative				0.0%
<i>Anaplastic astrocytoma, grade III</i>					
1	exon 7	245	GGC→AGC	Gly→Ser	51.1%
2	negative				29.5%
3	negative				19.7%
4	exon 8	281	GAC→GAG	Asp→Glu	17.4%
	exon 8	282	CGG→TGG	Arg→Trp	
5	negative				6.9%
6	negative				0.1%
<i>Glioblastoma multiforme, grade IV</i>					
1	negative				27.6%
2	negative				23.0%
3	negative				2.2%
4	negative				0.6%
5	negative				0.4%
6	negative				0.3%
7	negative				0.3%
8	negative				0.3%
9	negative				0.3%
10	negative				0.2%
11	negative				0.1%
12	negative				0.0%
13	negative				0.0%
14	negative				0.0%
<i>Primitive neuroectodermal tumor, grade IV</i>					
1	exon 7	245	GGC→AGC	Gly→Ser	31.1%

AAS: aminoacid shift; BS: base shift; SI: staining index of p53 immunohistochemistry; SSCP: single-strand conformation polymorphism.

(1995) codons 175, 248, and 273 were mainly involved and therefore termed hot spots. These hot spots were found on the highly preserved domains II, III, IV, and V, which include the exons 5 to 8 of the p53 gene (Ohgaki et al., 1993).

The mutations found in the present study were all point mutations mostly in the highly preserved regions of the p53 gene, but did not involve the hot spots. Five of the six mutations found were missense mutations, in which another amino acid is inserted, and one was a silent mutation that leads to the same protein product. All missense mutations involved G:C pairs.

Our results regarding the frequency of mutation in respect to the different glial tumor entities are partly in line with the results of other groups. With respect to astrocytoma WHO grade I and II we found mutations in 10.5%, for anaplastic astrocytoma WHO grade III mutations were detectable in 33.3%. We added the frequencies of mutations taken from 13 studies including ours (Mashiyama et al., 1991; von Deimling et al., 1992; Frankel et al., 1992; Fults et al., 1992; Sidransky et al., 1992; Louis et al., 1993; Newcomb et al., 1993; Ohgaki et al., 1993; Chozick et al., 1994; Koga et al., 1994; Lang et al., 1994; Rasheed et al., 1994) for comparison (Table 2). Concerning low grade astrocytoma mutations were found in 21 of 127 studied cases (16.5%), for anaplastic astrocytoma the rate was 28 of 83 cases (33.7%). In contrast to the summary of previous studies regarding glioblastoma, which found mutations in 68 of 213 cases (31.9%), we found a frequency of 0% in 14 cases. This study also includes the very rare mutation of p53 gene in a pilocytic astrocytoma described earlier (Patt et al., 1996).

The fact that p53 mutations can already be found in tumors of low malignancy underlines the assumption that p53 mutations are an early genetic change in tumorigenesis of human glial malignancies.

Louis et al. (1993) and others found different SI in tumors with the same molecular mutation in their p53 immunohistochemical studies. Bischoff et al. (1990) concluded that this phenomenon is due to cell cycle dependent expression and phosphorylation of p53 protein.

Comparing the average SI of the different glial tumor entities, Jaros et al. (1992) reported that the average SI increased with tumor malignancy and was hence highest in the glioblastoma group. However, we found the highest average SI in the group of anaplastic astrocytoma (20.8%). This is in line with the investigation published by Louis et al. (1993) and might strengthen the hypothesis of a different pathogenesis of anaplastic astrocytoma and glioblastoma. Von Deimling et al. (1993) suggested the existence of two entities of glioblastoma, of which one group derives de novo and is not associated with mutation of p53 or alteration of p53 protein.

In our study the genetic analysis does not correlate with the immunopositivity on a significant basis. Since there was an overlap in p53 immunopositivity and p53

Alteration of p53 gene and protein in gliomas

Table 2. p53 mutation frequency in astrocytomas of different malignancies in recent studies.

STUDY	ASTROCYTOMA, GRADES I AND II	ANAPLASTIC ASTROCYTOMA, GRADE III	GLIOBLASTOMA MULTIFORME, GRADE IV
Chozick et al., 1994	2/16=12.5%	3/7=42.9%	12/21=57.1%
Deimling von et al., 1992	3/8=37.5%	4/14=28.6%	5/11=45.5%
Frankel et al., 1992	not examined	1/3=33.3%	13/33=39.4%
Fults et al., 1992	0/6=0.0%	5/14=35.7%	7/25=28.0%
Koga et al., 1994	2/6=33.3%	nd	nd
Lang et al., 1994	2/8=25.0%	3/16=18.8%	not examined
Louis et al., 1993	3/8=37.5%	4/12=33.3%	4/14=28.6%
Mashiyama et al., 1991	0/6=0.0%	nd	nd
Newcomb et al., 1993	not examined	not examined	17/37=45.9%
Ohgaki et al., 1993	3/11=27.3%	not examined	not examined
Rasheed et al., 1994	3/36=8.3%	6/11=54.5%	7/51=13.7%
Sidransky et al., 1992	1/3=33.3%	not examined	3/7=42.9%
Present study	2/19=10.5%	2/6=33.3%	0/14=0.0%
Σ	21/127=16.5%	28/83=33.7%	68/213=31.96%

nd: no differentiation between grades III and IV, Koga et al. reported a 38.5% (5/13) mutation frequency in both, grades III and IV astrocytic tumors, Mashiyama et al. reported a frequency of 23.1% (3/13). P53 mutation frequencies are given in absolute numbers of examined cases and in percentages.

mutation in tumors of the different WHO grades and entities, p53 protein will not play a role as a diagnostic marker, neither for tumor entities nor tumor malignancy. However, the SI correlates with the mutations found ($p \leq 0.05\%$). The average SI of specimen without mutation was significantly lower than the SI in cases with mutation. Thus, a significance of p53 gene and/or protein alteration for individual cases cannot be ruled out. Prospective studies with a careful clinical follow-up are needed to investigate this possible significance.

Our study demonstrated that routine paraffin-embedded material can properly be used for the methods described above. However, we only succeeded in amplifying 50 of 84 tumor specimens (62.5%). For more reliable investigation, cryostatic material should thus be favored.

Acknowledgements. The authors would like to thank Prof. H. Martin, Institute of Pathology, Oskar-Ziethen Hospital, Berlin and Prof. W. Jänisch, Department of Neuropathology, Clinical Center Brandenburg, Brandenburg, Germany, for providing the tissue samples. This study was partially financed by the BIOMED-I program (PL 931359) from the Commission of the European Communities.

References

- Bischoff J.R., Friedman P.N., Marshak D.R., Prives C. and Beach D. (1990). Human p53 is phosphorylated by p60-cdc2 and cyclin-B-cdc2. *Proc. Natl. Acad. Sci. USA* 87, 4766-4770.
- Bögler O., Huang H.-J.S., Kleihues P. and Cavenee W.K. (1995). The p53 gene and its role in human brain tumors. *Glia* 15, 308-327.
- Chozick B.S., Weiker M.E., Pezzullo J.C., Jackson C.L., Finkelstein S.D., Amblar M.W., Epstein M.H. and Finch P.W. (1994). Pattern of mutant p53 expression in human astrocytomas suggests the existence of alternate pathways of tumorigenesis. *Cancer* 73, 406-415.
- Deimling A. von, Eibl R.H., Ohgaki K., Louis D.N., von Ammon K., Petersen I., Kleihues P., Chung R.Y., Wiestler O.D. and Seizinger B.R. (1992). p53 mutations correlate with 17p allelic loss in grade II and grade III astrocytoma. *Cancer Res.* 52, 2897-2900.
- Deimling A. von, von Ammon K., Schoenfeld D., Wiestler O.D., Seizinger B.R. and Louis D.N. (1993). Subsets of glioblastoma multiforme defined by molecular genetic analysis. *Brain Pathol.* 3, 19-26.
- Frankel R.H., Bayona W., Koslow M. and Newcomb E.W. (1992). P53 mutation in human gliomas: comparison of loss of heterozygosity with mutation frequency. *Cancer Res.* 52, 1427-1433.
- Fults D., Brockmeyer D., Tullous M.W., Pedone C.A. and Cawthon R.M. (1992). P53 mutation and loss of heterozygosity on chromosome 17 and 10 during astrocytoma progression. *Cancer Res.* 52, 674-679.
- Jaros E., Perry R.H., Adam L., Kelly P.J., Crawford P.J., Kalbag R.M., Mendelow A.D., Sengupta R.P. and Pearson A.D.J. (1992). Prognostic implications of p53 protein, epidermal growth factor receptor, and Ki-67 labelling in brain tumors. *Br. J. Cancer* 66, 373-385.
- Kleihues P., Burger P.C. and Scheidhauer B.W. (1993). *Histological typing of tumors of the central nervous system*. 2nd ed. Springer-Verlag, Berlin, Heidelberg, New York.
- Kleihues P., Ohgaki H., Eibl R.H., Reichel M.B., Mariani L., Gehring M., Petersen I., Höll T., von Deimling A., Wiestler O.D. and Schwab M. (1994). Type and frequency of p53 mutation in tumors of the central nervous system and its coverings. *Cancer Res.* 135, 25-31.
- Koga H., Zhang S., Kumanishi T., Washiyama K., Ichikawa T., Tanaka R. and Mukawa J. (1994). Analysis of p53 gene mutation in low and high grade astrocytomas by polymerase chain reaction-assisted single-strand conformation polymorphism and immunohistochemistry. *Acta Neuropathol.* 87, 225-232.
- Lang F.F., Miller D.C., Pisharody S., Koslow M. and Newcomb E.W. (1994). High frequency of p53 protein accumulation without p53 gene mutation in human juvenile pilocytic, low grade, and anaplastic astrocytoma. *Oncogene* 9, 949-954.
- Lazaris A.Ch., Theodoropoulos G.E., Anstassopoulos P., Nakopoulou L., Panoussopoulos D. and Papadimitrou K. (1995). Prognostic significance of p53 and c-erbB-2 immunohistochemical evaluation in colorectal adenocarcinoma. *Histol. Histopathol.* 10, 661-668.
- Louis D.N., von Deimling A., Chung R.Y., Rubio M.-P., Whaley J.M., Eibl R.H., Ohgaki H., Wiestler O.D., Thor A.D. and Seizinger B.R. (1993). Comparative study of p53 gene and protein alteration in

Alteration of p53 gene and protein in gliomas

- human astrocytic tumors. *J. Neuropathol. Exp. Neurol.* 52, 31-38.
- Louis D.N. (1994). The p53 gene and protein in human brain tumors. *J. Neuropath. Exp. Neurol.* 53, 11-21.
- Mashiyama S., Murakami Y., Yoshimoto T., Sekiya T. and Hayashi K. (1991). Detection of p53 gene mutation in human brain tumors by single-strand conformation polymorphism analysis of polymerase chain reaction products. *Oncogene* 6, 1313-1318.
- McPherson M.J., Quirke P. and Taylor G.R. (1991). PCR - A practical approach. Oxford University Press. Vol 1, pp 1-14.
- Newcomb E.W., Madonia W.J., Pisharody S., Lang F.F., Koslow M. and Miller D.C. (1993). A correlative study of p53 protein alteration and p53 gene mutation in glioblastoma multiforme. *Brain Pathol.* 3, 229-235.
- Nigro J.M., Baker S.J., Preisinger A.C., Jessup J.M., Hostetter R., Cleary K., Bigner S.H., Davidson N., Baylin S., Devilee P., Glover T., Collins F.S., Weston A., Mondali R., Harris C.C. and Vogelstein B. (1989). Mutations in the p53 gene occur in diverse human tumor types. *Nature* 342, 705-708.
- Ohgaki H., Eibl R.H., Schwab M., Reichel M.B., Mariani H., Gehring M., Petersen I., Höll T., Wiestler O.D. and Kleihues P. (1993). Mutations in the p53 tumor suppressor gene in neoplasms of the human nervous system. *Mol. Carcinogenesis* 8, 74-80.
- Patt S., Gries H., Giraldo M., Cervós-Navarro J., Martin H., Jänisch W. and Brockmüller J. (1996). P53 gene mutation in human astrocytic brain tumors including pilocytic astrocytoma. *Hum. Pathol.* 27, 586-589.
- Rasheed B.K., McLendon R.E., Herndon J.E., Friedman H.S., Friedman A.H., Bigner D.D. and Bigner S.H. (1994). Alterations of TP53 in human gliomas. *Cancer Res.* 54, 1324-1330.
- Sanger F., Nicklen S. and Coulson A.R. (1977). DNA sequencing with chain-terminating inhibitors. *Proc. Natl. Acad. Sci. USA* 74, 5463-5467.
- Sidransky D., Mikkelsen T., Schwachheimer K., Rosenblum M.L., Cavenee W. and Vogelstein B. (1992). Clonal expansion of p53 mutant cells is associated with brain tumor progression. *Nature* 355, 846-847.
- Sirvent J.J., Salvadó M.T., Santafé M., Martínez S., Brunet J., Alvaro T. and Palacios J. (1995). p53 in breast cancer. Its relation to histological grade, lymph node status, hormone receptors, cell-proliferation fraction (ki-67) and c-erbB-2. Immunohistochemical study of 153 cases. *Histol. Histopathol.* 10, 531-539.
- Wray W., Boulikas T., Wray P.V. and Hancock R. (1981). Silver staining of proteins in polyacrylamid gels. *Anal. Biochem.* 118, 197-203.

Accepted November 21, 1996